

Clinical Evaluation of the Result of Dorgan's Lateral and Conventional Cross K-Wire Fixation in Supracondylar Fracture Humerus in Children-A Comparative Study.

Dr SaikatSau.¹, DR Chinmoy Biswas²,
Dr Hibjul Ali Khan³

¹ms-Orthopaedics,Dnb Orthopaedics Senior Resident.Sskm Hospital.

²dnb -Orthopaedics² assistant Prof Dept Orthopaedics.Bankura Medical College.

³ms- Orthopaedics .Rmo Cum Clinical Tutor. Sskm Hospital.

Abstract: Supracondylar fracture is most common fracture in child around elbow. There are many techniques described in the literature. Conventional cross k wire technique medial k- wire can damage ulnar nerve, due to confusion to palpate medial epicondyle in swollen condition. Lateral retrograde k-wire (DORGAN technique) can prevent ulnar nerve injury. We treat 30 patients of supracondylar fracture with conventional cross k wire technique and DORGAN's lateral retrograde technique. We have done a comparative study. Clinically no difference between these two, but DORGAN technique is easy and decrease chance of ulnar nerve injury, as well as give same biomechanical stability.

Keyword: supracondylar fracture, Dorgan's technique, ulnar nerve.

I. Introduction

Supracondylar humerus fractures (SHF) are among the most common fractures in children, and completely displaced fractures usually necessitate surgical treatment.⁽¹⁾

Between the olecranon fossa posteriorly and the coronoid fossa anteriorly, the medial and lateral columns of the distal humerus are connected by a thin segment of bone, which makes this area especially vulnerable to fracture. The most commonly accepted treatment for the displaced SHF in children is closed reduction and percutaneous pin fixation.³⁻⁵ Completely displaced fractures usually necessitate surgical treatment. Several pin fixation techniques have been described including crossed pins and lateral pins.^{6,7} Biomechanical studies have shown that the maximum stability was provided by 2 crossed pins placed from the medial and lateral condyles.^{8,9}

Although ulnar nerve injury up to 6% from use of a medial pin is common, and this possibility is most likely to occur when the medial epicondyle cannot be palpated in swollen elbows.¹⁰ There are many techniques for Kirshner (K) wire fixation,

In supracondylar humerus fracture among them conventional k wire fixation is most popular surgical method. Controversy exists about the optimal k wire configuration in displaced type II & III fracture. We are using an alternate method of fixation with very minimum complications.

In our study we compare the outcome of displaced supracondylar fractures fixed by conventional cross k wire technique in one group, and another group of patients operated by two cross k wire from lateral side.

The study was designed to also give us a chance to understand the distribution and epidemiology of these kind of fractures, during the progress of therapy by different modalities.

II. Material Method.

The study was conducted in IPGME & R KOLKATA. ORTHOPAEDICS dept over a period of one and half years from January 2013 to June 2014.

Patients Selection

Out of the 60 patients 26 patients fitted our criteria for study.

Inclusion Criteria

1. Supracondylar fracture of humerus Gartland type II & III
2. Close fracture with out distal neuro vascular injury.
3. Fresh fracture with in One week.

Exclusion Criteria

1. open fracture. 2. undisplaced fracture.
3. associated with other serious co morbid condition.

III. Surgical Techniques

Every patient was thoroughly examined at the time of admission. The first step was to assess the vascular status of the limb. Once, the case was deemed to be without vascular deficit (defined as absent or feeble <50% of the volume on the other side), and then evaluation was done using other exclusion and inclusion criteria. The median (with anterior interosseus) radial and ulnar nerves were tested and the finding documented. The skin condition and the amount of swelling were assessed. Fractures classifications were done by radiographs. Check radiographs of the elbow were taken again if required in the anteroposterior and the true lateral planes if possible. The elbow was immobilized in a posterior long arm plaster of paris slab in the comfortable position of 50-60° of flexion. Analgesics were given, and the arm elevated to decrease swelling. The main investigator would perform the randomization by drawing lots – odd numbers signify medial-lateral pin fixation while even numbers would be treated by two lateral pin fixations by Dorgan method.

Closed reduction is performed in stepwise manner with minor modification of Rang's technique⁽²⁶⁾. Longitudinal traction is applied to the forearm while countertraction is applied to the proximal humerus. Posterior translation of the distal fragment may be corrected as the fragments disengage. An AP image is obtained at this point, and appropriate force is applied to the distal fragment to correct medial or lateral translation .

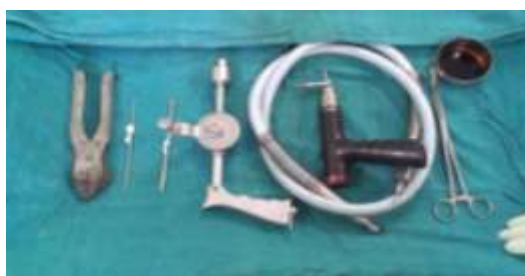

fig-1

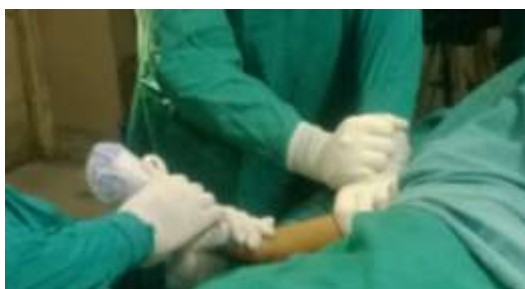

fig-2

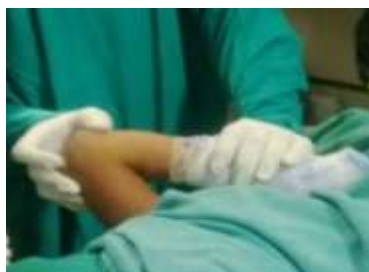

fig-3

fig-4

FIG-1- instrument needed for this operation.

Fig-2,3 –reduction method..fig-4—bluprint for conventional k wire fixation,and DORGAN'S lateral k wire technique.

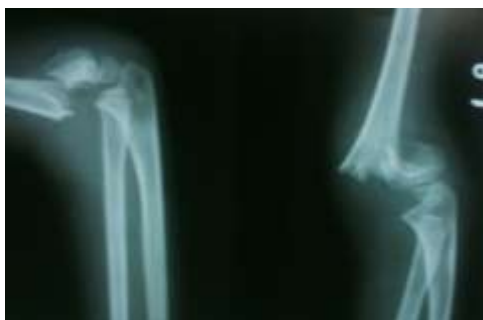

fig-5

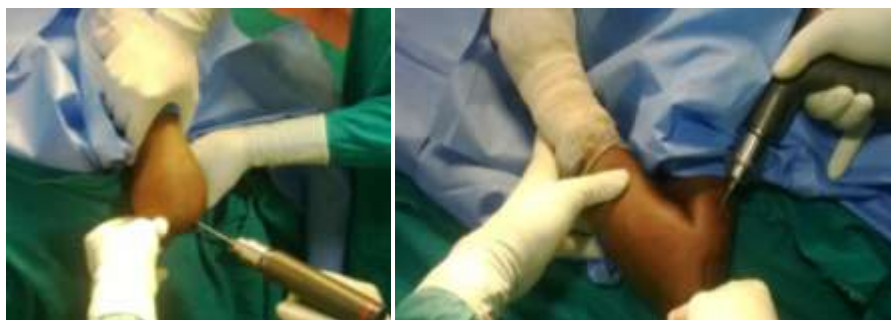

fig-6

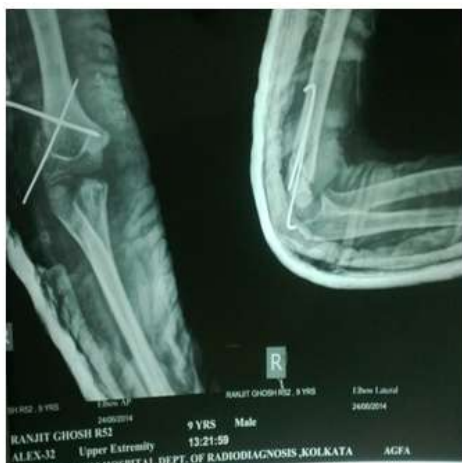

fig-7

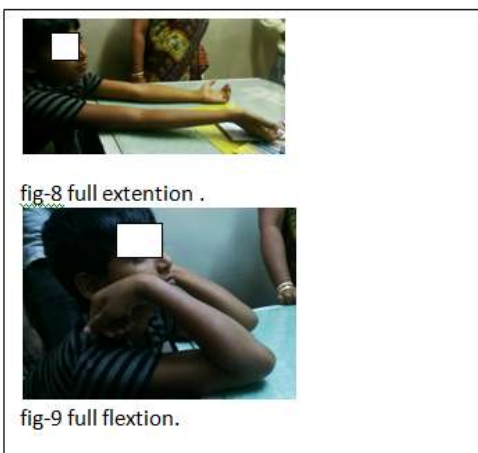

Fig-5- pre op fracture status.,fig-6 –k wire fixation method.fig-7 –post op reduction. All patients were operated in supine position under general anesthesia within 48 h of admission. Tourniquet was not applied. The first reduction manoeuvre was performed with traction applied to the forearm with an assistant applying counter traction. First, the medial or lateral displacement of the fracture was corrected. After that rotational displacement was reduced with pronation and supination of the forearm. Final, fixation by smooth K-wire into the medial condyle from the lateral side. The medial condyle should not be penetrated to avoid ulnar nerve injury, but cortical involvement could be achieved (Figure 1). The principal is that the wires should cross above the fracture line. The similar way, conventional method of cross fixation was done (Figure 2). Post-operative immediate neurological assessment for median, ulnar, and radial nerves, and anteroposterior and lateral X-rays were performed. The patients with iatrogenic ulnar nerve lesions in both groups were followed up without any treatment. The mean

hospitalization period was 1.7 days (range 1-5 days). We removed the cast K-wires after three weeks and started gentle active elbow exercises. At the last follow-up, we evaluate a range of motion and carrying angle by goniometer at both elbows. We evaluate the functional and cosmetic results according to the criteria proposed by Flynn *et al.* (Table 1).

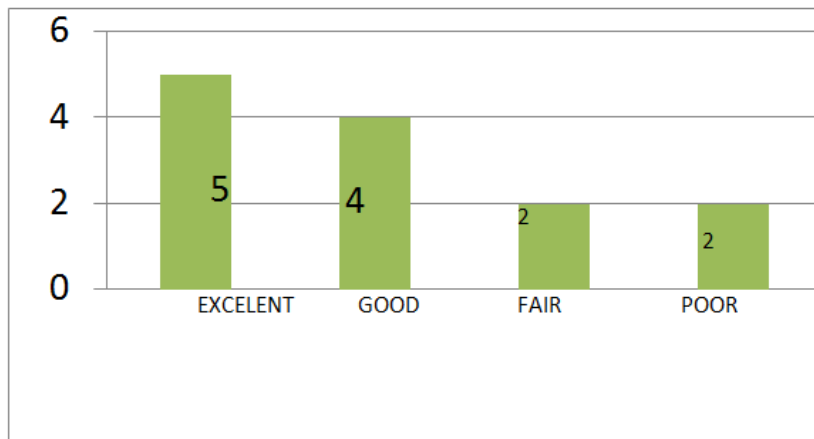
IV. Result And Analysis

Our study including 26 patients of closed supracondylar humerus Gartland type II and III. Two of them were extension type. Study was conducted at IPGME&R KOLKATA. Patients range from 5 years to 12 years. (average - 7.51 yrs).

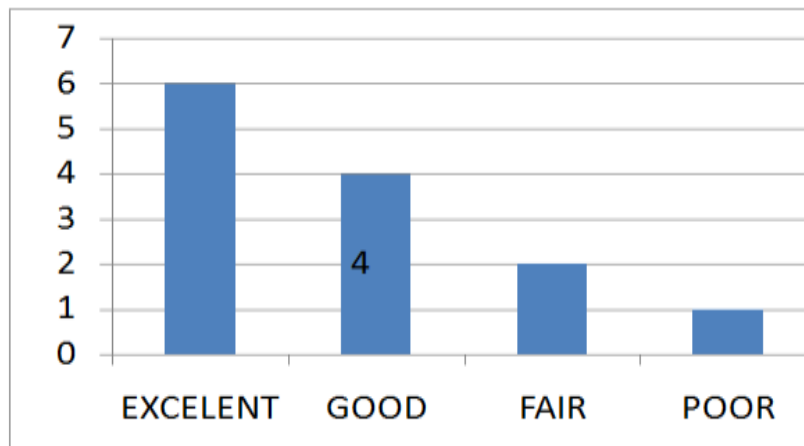The most frequent age group affected was 5-6 years. They were admitted and operated and followed up for a period ranging from 13 months to 5 months average 8.35 months. Clinical evaluation was based on modified Flynn's criteria.

Table 1: Modified Flynn's criteria to evaluate outcome of treatment
 Outcome Loss of elbow ROM (°) Loss of carrying angle (°)

Excellent 0-5 0-5
 Good 6-10 6-10
 Fair 11-15 11-15
 Poor >15 >15



Result of Dorgan's lateral k wire technique.



Results of conventional cross k wire technique.

For comparison of the result of both these procedures (conventional and DORGAN tech) we had to use universally accepted FLYNN'S CRITERIA, as well as with other published works..

To avoid statistical problem during comparison of these two groups, we decided to make two groups. One with both EXCELLENT & GOOD results and another with FAIR & POOR results combined together. Thus we could obtain a two by two contingency table and apply a statistical test to it.

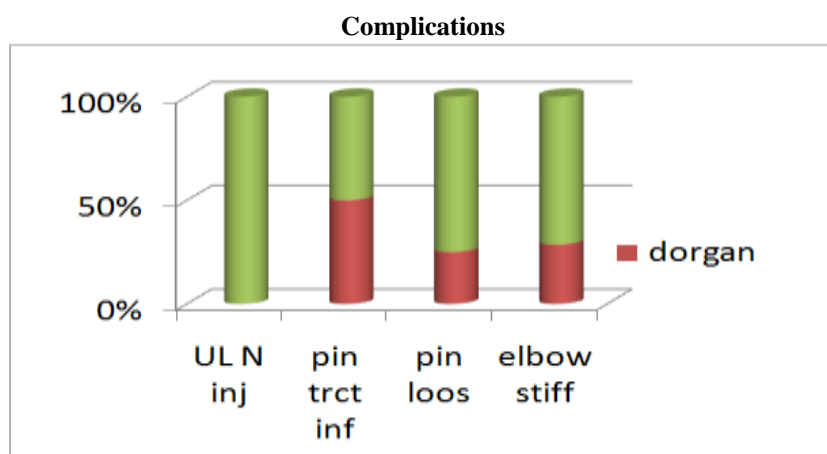
Since our sample size was small (26 cases only) and the chi-square test relies on a large sample approximation therefore, we preferred to use

"FISHER'S EXACT TEST" as in situations where a large sample approximation is inappropriate the ideal test to compare the results fairly was a Fisher's exact test. Based on exact probabilities from a specific distribution.

When this data was applied and an exact test done the values we obtained were

The p-value for the same or a stronger association = 0.4999999*

The p- value for the same or the reverse association=0.810869*
 Two sided p –value (the sum of small p’s) =0.99
 since the two sides p-value was much
 greater than **>0.05**



V. Discussion

There is a lack of uniformity of opinion concerning the ideal method of treatment of displaced supracondylar fractures in children. Several treatment modalities have been recommended.^{(13, 14).}

Closed manipulation and percutaneous K-wire stabilization is the accepted, and most popular treatment of displaced supracondylar fractures of the humerus in children.^(3-6,14) Biomechanical studies have demonstrated that crossed pin constructs are significantly more stable than lateral pin fixation alone.^(2,9) The cross-wire technique was popularized in recent years by several authors.^(11,14-16)

The torque required to produce lateral K-wires were comparable to cross-wires in extension, varus, valgus, and rotational loading, but were inferior in axial rotation testing. The 2-wire cross fixation is the most commonly used and good results have been reported, but injury of the ulnar nerve when inserting the medial wire has been documented ranging from 2-8%.^(3-5,14) When we compare our findings of iatrogenic ulnar nerve injury in 1 patient of group 1, with none in group 2, we find that the most frequent problem faced while performing medial K-wire is iatrogenic ulnar nerve injury.^(10,14,16,17)

However, we also found that the ulnar nerve remains safe when performing cross K-wire application laterally. Theoretically, the radial nerve could be injured during insertion of the more proximal wire. However, the radial nerve is situated anterior to the lateral intermuscular septum at this level, and can be avoided by entering the skin posterior to the midcoronal plane.¹⁴

VI. Conclusion

we conclude that while both closed reduction and percutaneous fixation techniques provide the best mechanical stability and good union rate, Dorgan's lateral cross-wiring technique has the advantage of avoiding injury to the ulnar nerve. Further larger prospective series, with longer follow-up is mandatory to support these results.

Reference

- [1]. Herring JA, editor. Upper extremity injuries. In: Tachdjian's Pediatric Orthopaedics. 3rd ed. Philadelphia, PA: W. B. Saunders; 2002. p. 2115-250.
- [2]. Tolo VT, Skaggs DL, editors. Masters Techniques in Orthopaedic Surgery: Pediatric Orthopaedics. Philadelphia, PA: Lippincott; 2007. p. 1-15.
- [3]. Skaggs DL, Hale JM, Bassett J, Kaminsky C, Kay RM, Tolo VT. Operative treatment of supracondylar fractures of the humerus in children. The consequences of pin placement. J Bone Joint Surg Am 2001;83A:735-40.
- [4]. Sibinski M, Sharma H, Sherlock DA. Lateral versus crossed wire fixation for displaced extension supracondylar humeral fractures in children. Injury 2006;37:961-5.
- [5]. Khan AQ, Goel S, Abbas M, Sherwani MK. Percutaneous K-wiring for Gartland type III supracondylar humerus fractures in children. Saudi Med J 2007;28:603-6.
- [6]. Tripuraneni KR, Bosch PP, Schwend RM, Yaste JJ. Prospective, surgeon-randomized evaluation of crossed pins versus lateral pins for unstable supracondylar humerus fractures in children. J Pediatr Orthop B 2009;18:93-8.
- [7].

- [8]. Solak S, Aydin E. Comparison of two percutaneous pinning methods for the treatment of the pediatric type III supracondylar humerus fractures. *J Pediatr Orthop B* 2003;12:346-9.
- [9]. Beaty JH, Kasser JR, editors. Supracondylar fractures of the distal humerus. In: Rockwood and Wilkins' Fractures in Children. 5th ed. Philadelphia, PA: Lippincott Williams & Wilkins; 2001. p. 577-624.
- [10]. Weinberg AM, Castellani C, Arzdorf M, Schneider E, Gasser B, Linke B. Osteosynthesis of supracondylar humerus fractures in children: A biomechanical comparison of four techniques. *Clin Biomech (Bristol, Avon)* 2007;22:502-9.
- [11]. Wind WM, Schwend RM, Armstrong DG. Predicting ulnar nerve location in pinning of supracondylar humerus fractures. *J Pediatr Orthop* 2002;22:444-7.
- [12]. Shannon FJ, Mohan P, Chacko J, D'Souza LG. "Dorgan's" percutaneous lateral cross-wiring of supracondylar fractures of the humerus in children. *J Pediatr Orthop* 2004; 24: 376-379.
- [13]. Flynn JC, Matthews JG, Benoit RL. Blind pinning of displaced supracondylar fractures of the humerus in children. Sixteen years' experience with long-term follow-up. *J Bone Joint Surg Am* 1974; 56: 263-272.
- [14]. Kim WY, Chandru R, Bonshahi A, Paton RW. Displaced supracondylar humeral fractures in children: results of a national survey of paediatric orthopaedic consultants. *Injury* 2003; 34: 274-277.
- [15]. El-Adl WA, El-Said MA, Boghdady GW, Ali AS. Results of treatment of displaced supracondylar humeral fractures in children by percutaneous lateral cross-wiring technique. *Strategies Trauma Limb Reconstr* 2008; 3: 1-7.